

Brava and Autologous Fat Transfer Is a Safe and Effective Breast Augmentation Alternative: Results of a 6-Year, 81-Patient, Prospective Multicenter Study

Roger K. Khouri, M.D.
Marita Eisenmann-Klein, M.D.
Eufemiano Cardoso, M.D.
Brian C. Cooley, Ph.D.
Daniel Kacher, M.S.
Eva Gombos, M.D.
Thomas J. Baker, M.D.

Key Biscayne and Miami, Fla.;
Regensburg, Germany; Milwaukee,
Wis.; and Boston, Mass.



Background: Breast augmentation by autologous fat transfer is an appealing alternative in need of scientific validation.

Methods: In a prospective multicenter study, 81 women (age range, 17 to 63 years) wore the Brava device, a bra-like vacuum-based external tissue expander, for 4 weeks and then underwent autologous fat injection using 10 to 14 needle puncture sites into each breast in a three-dimensional fanning pattern (average, 277 ml volume injected per breast). Patients resumed Brava wear within 24 hours for 7 or more days. Pretreatment and posttreatment breast volumes were derived from three-dimensional volumetric reconstruction of magnetic resonance imaging scans, and outcomes were compared with a meta-analysis of six recent published reports on autologous fat transfer breast augmentation without expansion. Follow-up ranged from 12 months to 6 years (average, 3.7 years).

Results: Breast volume was unchanged between 3 and 6 months. Seventy-one of the treated women were compliant with Brava wear and had a mean augmentation volume at 12 months of 233 ml per breast compared with 134 ml per breast in published series without Brava ($p < 0.00001$). Graft survival was 82 ± 18 percent compared with 55 ± 18 percent without Brava ($p < 0.00001$). There was a strong linear correlation ($R^2 = 0.87$) between pregrafting Brava expansion and the resultant breast augmentation. There were no suspicious breast masses or nodules. Magnetic resonance imaging recognized a 16 percent incidence of fat necrosis easily identified at 1-year mammographic evaluation.

Conclusion: The addition of Brava expansion before autologous fat grafting leads to significantly larger breast augmentations, with more fat graft placement, higher graft survival rates, and minimal graft necrosis or complications, demonstrating high safety and efficacy for the procedure. (*Plast. Reconstr. Surg.* 129: 1173, 2012.)

CLINICAL QUESTION/LEVEL OF EVIDENCE: Therapeutic, IV.

Autologous fat transfer to the breast has a long and controversial history.^{1,2} In 1987, a position statement by the American Society of Plastic Surgeons³ banned the procedure out of concern that the grafts would not survive and could lead to calcification believed to be indistinguishable from

cancer with the xeromammographic technology of the time. However, radiologists today are better able to differentiate neoplastic processes from fat necrosis.⁴⁻⁶ Furthermore, because of many technical refinements,^{7,8} autologous fat transfer today holds

From the Division of Plastic Surgery, Florida International University; the Miami Breast Center; Klinik für Plastische und Ästhetische Hand- und Wiederherstellungschirurgie, Caritas-Krankenhaus St. Josef; Orthopaedic Surgery, Medical College of Wisconsin; Surgical Planning Laboratory and Radiology Breast Imaging, Brigham and Women's Hospital, Harvard Medical School; and the Department of Surgery, University of Miami.

Received for publication August 23, 2011; accepted November 29, 2011.

Preliminary study results presented at the Annual Congress of the American Society for Aesthetic Plastic Surgery, in Orlando, Florida, May 21 through 25, 2006; interim results presented

at the Annual Congress of the American Society of Plastic Surgeons, in Seattle, Washington, October 23 through 27, 2009.

Copyright ©2012 by the American Society of Plastic Surgeons

DOI: 10.1097/PRS.0b013e31824a2db6

Disclosure: Dr. Khouri has an equity interest in Brava, LLC, the manufacturer of the Brava device, and is an owner of the company that makes the Lipografter described in the article. The other authors have no financial interests to disclose.

much promise in plastic surgery.^{9–24} Therefore, in 2007, the American Society of Plastic Surgeons commissioned a Fat Graft Task Force that concluded that autologous fat transfer might be used for the breast “while the techniques and the results vary. . . leaving a tremendous need for high quality clinical studies.”²⁵ In 2009, the American Society of Plastic Surgeons lifted the ban on fat grafting for breast reconstruction while recommending cautious use for augmentation²⁶ because of concern for safety and efficacy, given the paucity of scientific studies.

Breast augmentation with liposuctioned fat has suffered from two fundamental limitations: the volume of fat that can be transferred in a single session and the percentage graft survival.^{18–22,27} In fact, there seems to be an inverse relationship between the two (i.e., the more fat grafted, the lower its survival rate).²⁸ Efforts at overcoming this have focused on harvesting techniques, fat manipulation, stem cells, and related approaches.^{13,17–20,23,24,27,29–72} Most studies report 50 to 60 percent survival and an augmentation in the 100-ml range on long-term follow-up.^{17–22,27} Of note, none made any attempt to improve the quality of the recipient breast.

To preserve the graft-to-recipient interface critical for revascularization and survival, fat grafts have to be dispersed as microdroplets. Because in the small breasts to be augmented there is physically no room for dispersal without crowding a large quantity of microdroplets, we postulated that preparation of the recipient breast by external expansion is the key missing ingredient.

The Brava device has been on the market for over 10 years as an external soft-tissue expander and has demonstrated modest, permanent augmentation after long-term use.^{73–77} Short-term use of Brava, however, causes a marked temporary increase in breast size and generates a very large fibrovascular scaffold that would be an ideal recipient for fat grafts (Khoury RK, personal observation). We undertook this multicenter, prospective, magnetic resonance imaging–documented study to determine the safety and efficacy of single-stage large-volume autologous fat transfer to the breast treated with the Brava external breast expander.

PATIENTS AND METHODS

This study was designed to optimize all potential variables. This includes low-pressure atraumatic fat harvest, minimal graft manipulation, and meticulous microdroplet grafting. Because a larger recipient has room in which to safely graft larger volumes and because it is well proven that Brava expansion enlarges the recipient breast, we

found it unethical to randomize Brava patients versus nonexpanded controls and arbitrarily condemn women to the morbidity and risks of surgery for a less effective procedure. Furthermore, because there are multiple recent peer-reviewed reports of autologous fat transfer breast augmentation without expansion, we elected to compare our Brava-expanded cohort to a meta-analysis of this well-established baseline.

On institutional review board approval (Concordia Clinical Research, Inc.; Breast Reconstruction and Augmentation with Brava Enhanced Autologous Fat Micro Grafting Protocol No. 2004-2, IRB COMM. No. 167), 81 women (Miami Breast Center, Key Biscayne, Fla., $n = 59$; Caritas-Krankenhaus St. Josef, Regensburg, Germany, $n = 12$; Harley Medical Center, London, United Kingdom, $n = 10$) who desired breast augmentation, were averse to implants, and who tolerated a 20-minute Brava test trial in the office were enrolled in the study. We performed 77 bilateral and four unilateral autologous fat transfer breast augmentations on 170 breasts. Patient ages ranged from 17 to 63 years and body mass index ranged from 15 to 28 (average, 19.8). Smokers were excluded. All enrolled were grafted despite wide variation in compliance with the requested pregraft Brava treatment¹ and despite the fact that four patients were noncompliant. Six patients did not return for follow-up magnetic resonance imaging, and although self-reports indicate they are complication-free, postprocedure breast volumetric measurements were not taken. Six of the earlier patients later underwent grafting a second time. However, we only analyzed the outcome of their first graft. Figure 1 shows the breakdown of the treated and compliant patient groups.

Before Brava expansion and in phase with her menstrual cycle, every woman underwent baseline magnetic resonance imaging with breast coils, intravenous gadolinium contrast, and fat subtraction. The patients were asked to wear the Brava external breast tissue expander for 10 hours/day for 4 weeks. This preexpansion period increases the vascularity of the recipient site.^{61,62,78} For the last 36 to 48 hours, they were asked to maintain uninterrupted expansion and come to the operating room still wearing the expander, to induce an immediate temporary three-dimensional enhanced enlargement of the subcutaneous periglandular tissue matrix (Fig. 2).

Harvesting and grafting were performed with the Lipografter, a closed fat harvesting, processing, and grafting device (KVAC Syringe and A-T Valve; Lipocosm, LLC, Miami, Fla.). The fat was

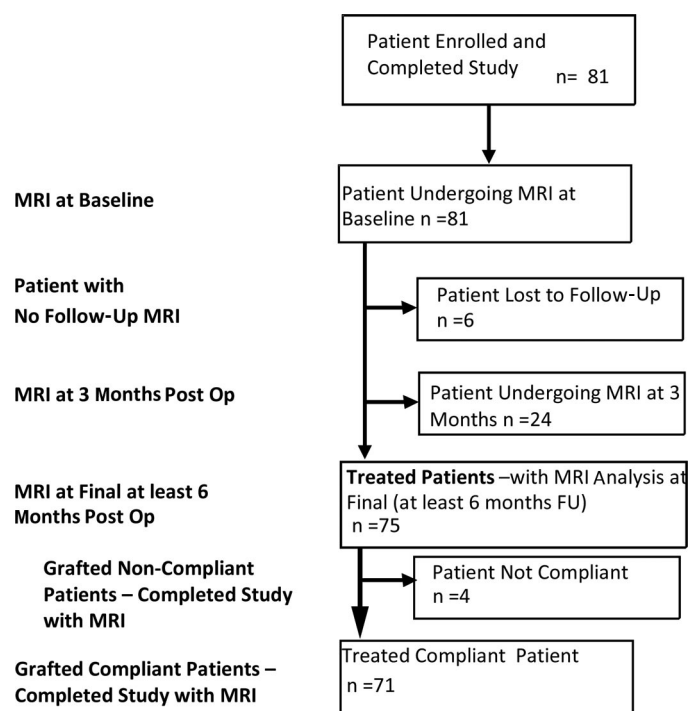


Fig. 1. Study design flowchart, showing sequence of magnetic resonance imaging (MRI) scans, with breakdown of numbers based on follow-up (FU) and Brava use compliance.

aspirated with a 12-hole, 2.7-mm cannula (Marina Medical, Sunrise, Fla.) attached to a spring-activated KVIC syringe pulling a constant 300-mmHg vacuum. The aspirate was transferred directly from the syringe to a collection bag through a nonclogging three-way A-T Valve and the bags were centrifuged at 15 *g* for 3 minutes. The supernatant fat was then reinjected directly from the bag using the A-T Valve in reverse using 3- to 5-ml syringes and 2.4-mm single-sidehole blunt 15- to 25-cm reinjection cannulas. We grafted the breast through a multitude of perimammary and periareolar needle puncture sites, injecting no more than 1 ml per 5 cm of cannula retraction, microweaving the grafts and fanning the passes radially around each injection site. Adequate pre-expansion allowed us to layer the grafts in three planes, the immediate subdermal, the deeper mastectomy level, and an intermediate subcutaneous plane. We avoided the peau d'orange effect of subcutaneous overfilling. We then proceeded to graft the subglandular tissue, the pectoral muscle, and the subpectoral plane, strictly avoiding the breast parenchyma. We carefully avoided localized collections and overgrafting as assessed by tissue turgor. A supportive conforming breast bandage was applied at the end of the procedure.

Within 24 hours after the procedure, patients removed all dressings, took a shower, and wore the Brava device for the next 48 to 72 hours uninterrupted to hold up the grafts as stents during the revascularization and early engraftment period. On the third postoperative day, they were encouraged to return to their normal lifestyle and to wear the Brava device only at night for 4 more days. If Brava use was well-tolerated, they continued wearing it a few hours per day, tapering the wear over an additional few weeks. Patients were seen on a quarterly basis for the first year and then only on an as-needed basis. Final follow-up was by means of electronic mail or telephone. At 3 months after grafting, a second magnetic resonance imaging scan was obtained on the first 24 patients, and all underwent final magnetic resonance imaging at 6 to 12 months. All women older than 40 years underwent mammography at 1 year complemented by an ultrasound examination whenever indicated by the radiologist. Two independent teams of breast radiologists reviewed the mammograms and magnetic resonance imaging scans.

Baseline and final breast volume measurements were derived from magnetic resonance imaging scans viewed in axial orientation with the Digital Imaging and Communications in Medicine

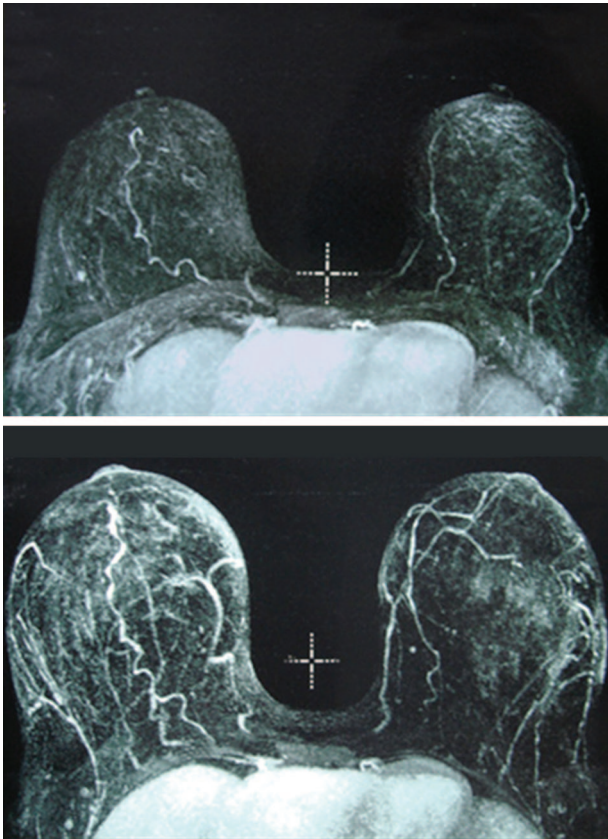


Fig. 2. Magnetic resonance imaging scans of breasts with contrast in a patient before (*above*) and after 3 weeks of 10 hours/day of Brava use (*below*). Note the enlarged parenchyma and the marked increased vascularity in the image *below* (after Brava use).

standard. The breast area was outlined for sections at 1-mm intervals, including the skin and basing the internal margin on consistent anatomical landmarks (e.g., sternum, pectoralis, shoulder features). Areas were summed to yield a volume approximation for each breast, measured in milliliters.⁷⁹ Maximal expansion volume was derived photographically by comparing the standard set of three poses obtained at the time of maximal expansion on the day of surgery with two other sets of the exact same three poses taken at the baseline and at the final breast volume measurements, both with known magnetic resonance imaging–derived measurements. The injected graft volumes were recorded during the procedure.

Statistical analysis was performed on three endpoints: augmentation volume, defined as final – baseline breast volume measurement; percentage augmentation, defined as $[\text{augmentation volume} / \text{baseline}] \times 100$; and graft survival rate, defined as $[\text{augmentation volume} / \text{injected graft volume}] \times 100$.

Data extracted from six recently published clinical studies,^{18–23} which did not use expansion before autologous fat transfer, were combined and used as a control group (total sample size, $n = 335$).^{80–82} Of these, four ($n = 280$) reported autologous fat transfer augmentation using various means of harvesting and fat separation,^{18,20,21,23} and two ($n = 55$) used stem cell–enhanced technology (which involves the addition of processed fat and concentrated stem cells).^{19,22} Table 1 shows the graft retention rates based on outcomes from these studies, with a mean graft retention rate of 55 percent. The data for our series were compared using paired t tests (before treatment versus after treatment). For comparison of the percentage augmentation with the previously published pooled control group, we used a two-sample independent-variance t test.

In addition to the comparison of the mean retention rate and augmentation volumes of the published autologous fat transfer control and our autologous fat transfer plus Brava–treated groups, a dose-response curve was developed to measure the effect of preexpansion on fat volume transferred, using a paired t test. All enrolled women were asked to use the Brava device for 10 hours/day for 4 weeks. However, some were more compliant than others; and some, with involutional atrophy, had tissues that were more compliant than the younger, tighter nulliparous breasts. Thus, we observed a marked variability in the amount of pregraft breast expansion that allowed us to build a dose-response curve of expansion versus augmentation.

To further analyze the relationship between expansion and augmentation, a regression analysis was performed on the sample of 75 women. The

Table 1. Analysis of Six Published Articles Using Autologous Fat Transfer without Expansion

Reference	Sample Size	Mean	SEM*	Lower Limit	Upper Limit
Zocchi and Zuliani, 2008 ²⁰	181	0.5500	0.016	0.519	0.581
Wang et al., 2008 ¹⁸	33	0.4900	0.003	0.484	0.496
Yoshimura et al., 2008 ¹⁹	40	0.5500	0.041	0.467	0.633
Delay et al., 2009 ²¹	30	0.6500	0.013	0.624	0.676
Yoshimura et al., 2010 ²²	15	0.5600	0.076	0.397	0.723
Ueberreiter et al., 2010 ²³	36	0.5168	0.020	0.477	0.557
Total	335	0.5528	0.0281	0.495	0.611

*Sample variance used to compute the SEM was calculated from data provided in the study.

data were normalized by dividing both variables by baseline volume. Maximal expansion/baseline volume was used as the independent variable and augmentation/baseline volume was used as the dependent variable. Descriptive statistics were calculated and their relationship analyzed using MATLAB 7.8.0 (MathWorks, Natick, Mass.) and the function “cftool.”

RESULTS

Of the 84 women evaluated for enrollment in the study, three (3.6 percent) were turned away for failure to pass the Brava tolerance test in the office. We progressively increased graft volume as we became more comfortable with the procedure. The first 20 women were grafted conservatively with an average of 190 ml per breast, resulting in 90 percent graft survival, whereas the latest 20 were grafted an average of 360 ml per breast with 78 percent measured graft survival. Operating time for the first 20 cases averaged 4 hours and later decreased to 2 hours despite larger volumes as we developed the Lipografter to increase harvesting and grafting proficiency. There were no surgery-related complications. Average follow-up was 3.7 years (range, 12 to 75 months). Except for temporary bruising and superficial skin blisters that healed uneventfully, there were no significant complications, and all women returned to sedentary activities within 3 to 4 days and full activities within 1 week, with the liposuctioned donor sites as the only foci of morbidity. One patient developed a late (2 months postoperatively) atypical mycobacterial infection treated successfully with oral antibiotics and minor incision and drainage. Six women had unplanned pregnancies within 6 months after grafting. All had normal deliveries and breastfed. Follow-up magnetic resonance imaging scans were obtained 1 year after they stopped breast-feeding. None of the patients developed clinically suspicious breast masses or nodules. Although some women had minor weight fluctuations during the course of the study, the overall average body mass index did not change. All were very pleased with the enlargement and improved appearance of their breasts and liposuctioned donor sites (Figs. 3 through 5).

The 3- and 6-month magnetic resonance imaging scans were essentially unchanged ($p > 0.4$, paired t test), indicating that whatever graft survived at 3 months was stable. There were recognizable foci of fat necrosis in 12 of the 75 women. At 1 year, only these same 12 women (16 percent) showed some calcifications on mammography. All calcifications were clearly recognizable as benign

fat necrotic foci. Because they were determined to be not suspicious for malignancy, they required no further intervention. Every focus of fat necrosis identified by magnetic resonance imaging was also recognized as a benign oil cyst by mammography, confirming that in this series, the 1-year mammogram was as sensitive as magnetic resonance imaging for the detection of fat necrosis. Because there was no change between the 3- and 6-month magnetic resonance imaging scans, the subsequently enrolled 47 women had only one magnetic resonance imaging scan at a minimum 6-month follow-up (average, 1 year). One of the 6-month follow-up magnetic resonance imaging scans was read as equivocal, requiring a repeated study 6 months later that confirmed the benign nature of the lesion.

Table 2 lists summary breast volumetric data of the 71 Brava-compliant autologous fat transfer-treated patients. The average volume of fat grafted was 282 ml per breast, with a resultant average augmentation of 233 ml per breast (range, 60 to 619 ml; SD, 108 ml per breast). Table 3 summarizes the published autologous fat transfer breast augmentation control series. Based on the available data ($n = 124$), the mean volume of fat grafted was 249 ml per breast, with a resultant weighted average volume augmentation of 134 ml per breast (range, 63 to 223 ml per breast; SD, 43 ml per breast). Statistical comparison of augmentation volumes achieved with Brava plus autologous fat transfer is significantly greater than the published series of autologous fat transfer augmentations ($p < 0.00001$, two-sample independent-variance t test).

The weighted mean graft retention rate of the published control patients ($n = 335$) was 55 percent, with a weighted SD of 18 percent. In our treated patients ($n = 75$), the mean graft retention rate was 78 percent (range, 0 to 129 percent). However, the mean retention rate for the treated compliant sample ($n = 71$) was 82 percent (range, 40 to 129 percent; SD, 18 percent) ($p < 0.00001$, two-sample independent-variance t test).

A dose-response curve illustrating the relationship between pregrafting Brava expansion (dose) and final breast augmentation (response) was developed. The expansion and augmentation data were normalized by dividing each variable by baseline volume, creating a ratio plotted in Figure 6. The correlation of determination (R^2) between the two was initially derived using the linear least squares method. However, because there are several outliers in the data that weigh heavily on the fit, we used the “robust fit”³ method, which de-



Fig. 3. Images of a woman with pectus deformity and asymmetry (*above*), showing maximal expansion just before fat grafting with the markings of the injection sites (*center*). Pectus and asymmetry have been corrected and stable augmentation has been achieved at 2.5-year follow-up (*below*).

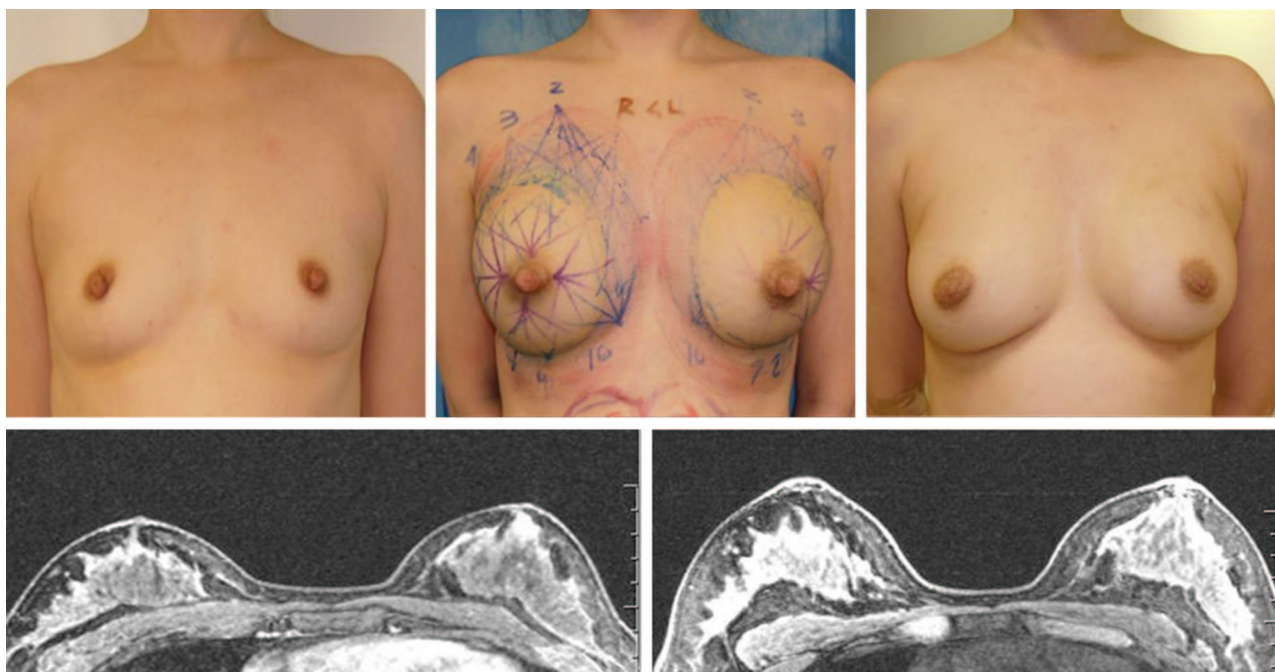


Fig. 4. A 24-year-old Asian nulliparous woman is shown before expansion (*above, left*) and after maximal pregrafting expansion with markings of needle puncture sites for the grafting cannulae (*above, center*). Her appearance after augmentation result at 1-year follow-up (*above, right*). (*Below, left*) Preoperative and (*below, right*) postoperative magnetic resonance imaging scans; note the periglandular fat graft. Volumetric three-dimensional reconstruction documented 260 ml of augmentation per breast.

emphasizes outliers to achieve an alternative fit. Figure 6 shows the robust fitted curve and its respective confidence interval boundaries.

Figure 7 illustrates the correlation between preoperative Brava expansion and augmentation volume. We subdivided the patients into four groups depending on their expansion ratio. Women who were not compliant and were poorly expanded could be considered as nonexpanded controls. They ended up with augmentation volumes comparable to the published autologous fat transfer series, whereas those who doubled or tripled their baseline volume as a result of Brava expansion achieved augmentation volumes comparable to moderate sized implants.

DISCUSSION

Fat grafting is an established procedure for the face where very small volumes are grafted in a highly vascular recipient site.^{32–36,46,50–52,83–85} It is also well accepted for the buttocks, where larger volumes are grafted in a large recipient site and where calcifications and nodules are less worrisome.^{48,86–88} However, fat grafting to the breast has remained controversial for two main reasons: (1) our inability to transfer large volumes of fat in a small recipient breast and predictably expect a high graft survival rate, and (2) our perceived inability to distinguish

graft failure nodules and calcifications from cancer. The inability to optimize these outcomes has spurred a great deal of interest and experimentation. Our data show that external expansion of the recipient breast with Brava before and after the procedure enables the physician to achieve an increase in volume and graft survival significantly superior to what can be achieved without it. Statistical analysis shows that the extent of preoperative expansion is a major determinant of final augmentation volume.

Pregrafting expansion creates a larger and more fertile recipient matrix that will allow more fat graft droplets to be diffusely dispersed, with each maintaining the crucial graft-to-recipient interface contact required for revascularization.⁷¹ A number of surgeons have shown acceptable results using a variety of fat harvesting and preparation methods, some often diametrically opposite to each other.^{29,31,40,41,43,45,49,54,89–114} Interestingly, the control studies reviewed in this article used various graft preparation methods, including stem cell-enriched fat to yield similar results. Our experience points to the fact that the rate-limiting factor in large-volume autologous fat transfer is the recipient site, not the graft material and its harvesting and preparation.

Large-volume autologous fat transfer is three-dimensional grafting, a novel concept requiring

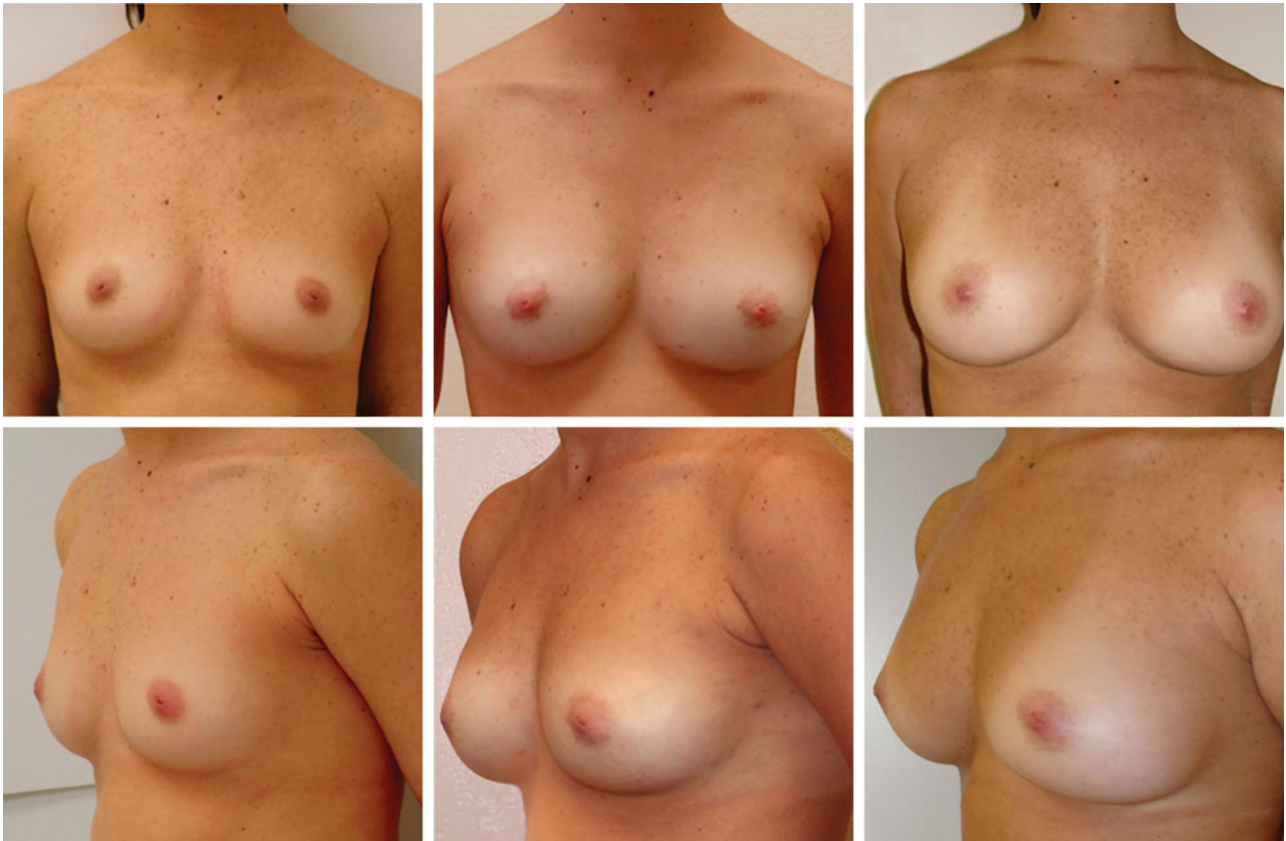


Fig. 5. A 31-year-old nulliparous woman is shown before treatment (left) and at 6-month (center) and 5-year follow-up (right). Breasts are soft, with no masses, and stable augmentation.

Table 2. Magnetic Resonance Imaging Analysis and Volumetric Statistics of 71 Treated Brava-Compliant Patients*

Statistic	Baseline Volume (ml)	Maximum Expansion Volume (ml)	Grafted Volume (ml)	Final Volume (ml)	Augmentation Volume (ml)	Expansion Volume (ml)
Minimum	85	250	90	200	60	70
Maximum	1015	1290	600	1230	619	741
Mean	371	678	282	605	233	306
SD	173	236	112	223	108	130

*Greater than 20 percent expansion.

conceptual thinking akin to sowing seeds in a field. To yield the best crop, we need to optimize the following four components aligned in series such that each can be rate limiting:

- The seeds (e.g., the graft, its quality, viability, fat inductive ability).
- The planting method (e.g., the surgical technique of diffusely, evenly and atraumatically sowing to avoid clumps, collections).
- The field (e.g., the recipient tissue, its size, its vascularity, the presence or absence of growth promoting factors).

- The nurturing of the seedlings after planting (e.g., postoperative care, immobilization, stimulation of growth).

If only one of the above components is poor, even if all others are maximized, the final yield will be poor. It is the least optimized of these four components, the bottleneck factor, which becomes the rate-limiting step and the one that determines the overall result.

Before seeding, the farmer prepares the land to accept the seeds by plowing and tilling the soil. Brava works in a similar way. When the device is worn before the procedure, it preexpands the recipient matrix,

Table 3. Control Group Data

Reference	Treatment	No.	Grafted* (ml)	Augmented† (ml)	Graft Survival Rate‡ (%)	SD§ (%)
Zocchi and Zuliani, 2008 ²⁰	AFT¶	181	—	—	55.00	21
Wang et al., 2008 ¹⁸	AFT¶	33	275	129	49.48	2
Yoshimura et al., 2008 ¹⁹	CAL¶	40	273	150	55.01	26
Delay et al., 2009 ²¹	AFT¶	30	—	—	65.00	7
Yoshimura et al., 2010 ²²	CAL¶	15	264	149	56.55	29
Ueberreiter et al., 2010 ²³	AFT¶	36	184	110	51.68	12
Total		335		134	55	

AFT, autologous fat transfer; CAL, cell-assisted lipotransfer.

*“Grafted” involves the addition of processed fat and concentrated stem cells. The volume (ml) of fat injected into the breast area is listed. The sample ($n = 124$) is the sum of the sample sizes in the studies by Wang et al.,¹⁸ Ueberreiter et al.,²³ Yoshimura et al.,¹⁹ and Yoshimura et al.²² Wang et al.’s calculations are the sum of five separate grafting procedures of between 50 and 60 ml/session, conducted 1 month apart.¹⁸ The articles by Delay et al.²¹ and Zocchi and Zuliani²⁰ do not provide injected volume data.

†Growth (in milliliters) for the articles by Wang et al.¹⁸ and Yoshimura et al.¹⁹ was computed from available data. The article by Yoshimura et al.²² explicitly provided the growth data figures. There were no volume data provided in the article by Delay et al.,²¹ and the growth data for the article by Zocchi and Zuliani²⁰ could not be computed.

‡Retention rate is the quotient of incremental growth divided by injected volume. Calculated from available data.

§Standard deviation of the mean retention rate was calculated from each control group’s available data.

¶Patient was deemed not to have been wear compliant when there was a less than 120 percent expansion before surgery.

¶Does not enhance the grafted fat in anyway (e.g., with stem cells).

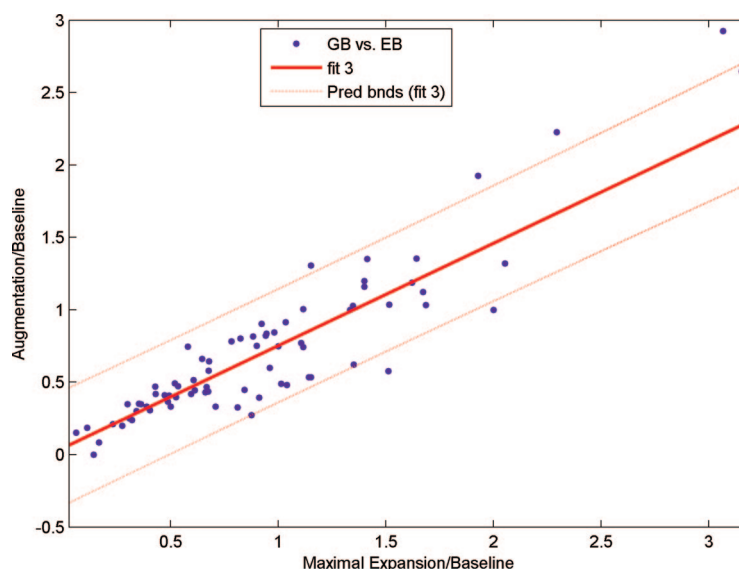


Fig. 6. Dose-response curve generated from the measure of maximal breast expansion immediately before fat grafting (x axis) and final 1-year follow-up magnetic resonance imaging measurement of breast augmentation volume (y axis). A strongly linear response is seen ($R^2 = 0.87$).

separating the tissue planes, increasing the parenchymal space, and reducing the interstitial pressure in the breast for a given level of fat injected. Without preexpansion, the fat plays the dual role of a graft in need of nutrients to survive and of an internal tissue expander. This is not a serious problem when small volumes of fat are transplanted because small amounts do not significantly affect physiologic interstitial pressure, and meticulous graft dispersion can still preserve adequate recipient interface for oxygen and nutrient diffusion in the early days after grafting. However,

even with the most meticulous grafting technique, increasing graft volumes has at least two deleterious effects: (1) increased interstitial pressure leading to decreased tissue perfusion and less engraftment potential; and (2) decreased graft-to-recipient interface in the crowded, recipient-isolated graft collections leading to necrosis/apoptosis of the grafts inadequately exposed to nutrients. By increasing parenchymal space, Brava expansion overcomes these two limitations of high-volume grafting. Instead of forcing their way under pressure to act as internal

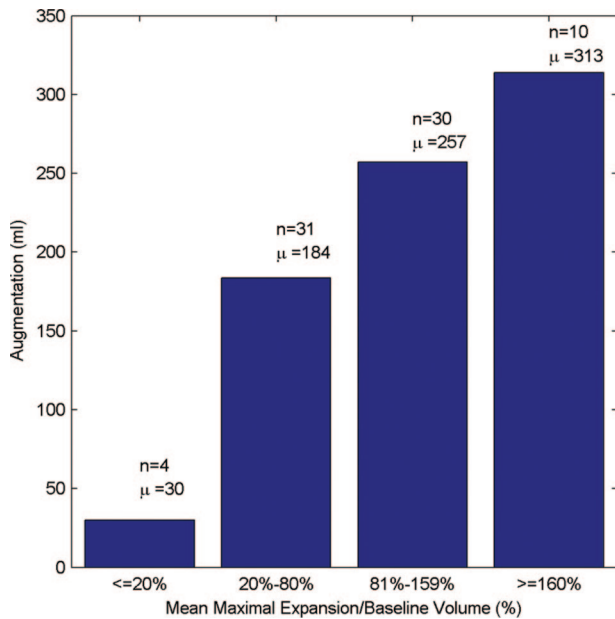


Fig. 7. Preoperative expansion ratio versus final augmentation volume. Patients segregated on the basis of maximal expansion from baseline (relative percentage), showing a strong trend for greater augmentation with increasing maximal expansion.

expanders, the grafted cells lodge themselves into an expanded fibrovascular scaffold and populate it. Furthermore, as has been shown with the vacuum-assisted closure device, vacuum and the mechanical force of expansion promote angiogenesis and the local elaboration and up-regulation of growth factors.^{61,62,115–118} This increased vascularity enhances the ability of the grafted tissues to feed and survive. It is well established that muscle tissue with its high capillary density is an excellent graft recipient bed and that, the more vascular the recipient, the better the graft survival.^{19,119–121} Therefore, pregrafting Brava preparation of the breast has dual beneficial effects: (1) a physical effect that increases space, reduces graft crowding and filling pressure, and generates a recipient scaffold; and (2) a biological effect that stimulates angiogenic cytokine production to improve engraftment.^{30,42,57,60,65,66,69,115,116,122–130}

After soil preparation, the farmer selects the best seeds to plant. Just like the farmer must have good seeds, the harvesting, processing, and reinjecting of adipocytes must be performed carefully. It is in trying to perfect these processes that most, if not all, of the energy and resources expended in autologous fat transfer have been focused over the past 20 years. However, no matter how much these areas are improved with new tools, methods, and technologies, they probably will never compensate for the rate-limiting factors of recipient-site adequacy,

interstitial pressure, and graft revascularization. These bottlenecks will remain.

Finally, after preparing the land and sowing good seeds, they must be nurtured. Reapplying vacuum immediately after the procedure plays a similar role; the vacuum immobilizes the grafts to allow neovascularization and stimulates the proliferation of the engrafted cells.^{117,118,131–134} From the face-grafting experience, it is well known that fat grafts in the mobile periorbital region are not as successful as grafts to other less mobile areas. At the very least, immediate postgraft immobilization is crucial. Using Brava postoperatively at low steady pressure helps nurture the graft by immobilizing it as a stent, protecting it from external trauma and keeping open millions of tiny “Morrison growth chambers,”^{135,136} which have been proven experimentally to stimulate fat graft growth. Furthermore, as has been reported, unless vascularization takes place within a relatively short period, cells do not survive.

Our multicenter prospective study reveals a strong dose-dependent effect of preoperative expansion to final augmentation. Statistics provide more than 80 percent certainty that the final augmentation will be approximately 70 percent of the peak Brava expansion. This takes away the unpredictability factor that has plagued autologous fat transfer. It also makes the patient responsible for her result and stimulates her to comply with Brava.¹³⁷ Compliant women achieve augmentation volumes comparable to those of implants in a single-stage (<2 hours), incisionless procedure. The procedure yields a natural appearing breast with the ability to correct deformities and shape the breast better than any “anatomical” implant.

Use of the Brava device is painless. Pain is an alarm for tissue injury, and at its earliest hint, the woman is asked to simply remove the domes. However, the use of Brava has been criticized as “difficult,” prompting surgeons to promote the practice of autologous fat transfer without Brava, especially in women with involutional atrophy. Unfortunately, these practitioners fail to understand the concepts of three-dimensional grafting and that of the farmer elaborated above. Loose, atrophied breasts have a lax skin envelope, but they still have the same parenchymal tissue density. Thus, a small loose breast is still a small recipient breast, and attempts to overfill that small dense tissue will invariably lead to crowding and graft loss. To avoid crowding, the interstitial space has to be spread open and a fertile recipient fibrovascular matrix has to be prepared with Brava expansion. Admittedly, loose breasts are more me-

chanically compliant and will respond very effectively to the Brava expansion. Thus, to give these women the best result possible in a single grafting session, it is best to convince them of the benefit of Brava and to provide them with encouragement and support during the expansion process. A very compliant patient with very compliant tissues can expand by 150 percent in 10 to 14 days and expect to double her original breast volume to yield an autologous tissue augmentation in the 300-ml range in a single, incisionless, outpatient procedure lasting less than 2 hours. In 2007, Del Vecchio visited our center and subsequently reproduced our results independently. Using a slightly different protocol of Brava preexpansion and fat grafting, he and coauthor Bucky recently published this initial experience that supports our findings.¹³⁸

Brava wear requires discipline and a commitment. If a woman cannot commit to a few weeks of Brava wear, the surgical alternatives are as follows: (1) proceed with an autologous fat transfer procedure without Brava and accept a modest augmentation in the 100- to 150-ml range; (2) subject herself to repeated autologous fat transfer procedures to achieve what she would have obtained in one stage had she used Brava; and (3) commit to a lifetime with implants. Typically, patients who opt for Brava plus autologous fat transfer are disciplined and more educated; these are crucial requirements for compliance. It is no surprise therefore that 86 percent of the women in our series have at least a college degree and that 20 percent are in the medical field or are immediate family of physicians and that four are radiologists.

Liposuction and breast augmentation consistently top the list of the most commonly performed aesthetic surgery procedures. Brava plus autologous fat transfer provides both at the same time. It is a two-for-one procedure, as we most often removed fat from where it is unwanted and put it where it is desirable, fulfilling the age-old dream of total body reshaping without a single incision.

As to the primordial issue of patient safety, in our 6 years of experience with 170 breasts augmented with Brava plus autologous fat transfer, our main complication was one atypical bacterial infection that was treated successfully and healed with no significant sequelae. We also had one magnetic resonance imaging scan that showed an equivocal lesion, and that breast was cleared on follow-up study. This 1.3 percent (one of 75) is an expected false-positive rate of breast magnetic resonance imaging.¹³⁹ It is important to note that, although there were a few fat necrotic foci, these

were readily identified and that none of the patients had suspicious lesions requiring biopsy. This confirms recent reports that modern breast imaging technology can almost always distinguish a fat necrotic nodule from a neoplastic lesion. Radiologists are now realizing that quite to the contrary of obscuring the breast, autologous fat transfer adds to the breast a radiolucent tissue that renders it less dense.

Finally, some skeptics have perniciously raised the possibility that autologous fat transfer could cause or enhance breast cancer. In humans, there is absolutely no scientific support for that claim, even theoretical. The American Society of Plastic Surgeons task force did not find any, and it would be preposterous to claim that a patient's own tissues harvested from one site and transferred to another site, as is, without any manipulation would become a carcinogen. This indictment shatters the very core of plastic surgery, as the tissue transfer specialty. We have been transferring massive amounts of fat into cancer-prone residual post-mastectomy defects with no shred of evidence that this leads to an increase in recurrence rate. Furthermore, careful epidemiologic review of the French and Italian experiences with autologous fat transfer to hundreds of highly cancer-prone irradiated lumpectomy defects followed for 10 years did not reveal any increase in cancer recurrence.^{27,140} Recent reviews have confirmed the oncologic safety of autologous fat transfer,¹⁴¹ and although women should always monitor their breasts, this is not an issue that should deter the acceptance of this highly satisfactory alternative and most natural method of breast augmentation.

CONCLUSIONS

More than 20 years after the American Society of Plastic Surgeons banned fat grafting to the breast, the debate and controversy surrounding this procedure can be laid to rest. Our study shows that Brava breast expansion enables the transfer of large volumes of fat in a single session safely and effectively while ensuring a very high survival rate, with augmentation volumes comparable to implants and the added benefit of a more natural appearance and feel. This radiographically monitored long-term follow-up of a large prospective multicenter study establishes a benchmark and a platform for further potential improvements.

Roger K. Khouri, M.D.

Miami Breast Center
580 Crandon Boulevard
Key Biscayne, Fla. 33149

drkhouri@miamibreastcenter.com

REFERENCES

1. Czerny A. Plastischer Ersatz der Brustdrüse durch ein Lipoma. *Chir Kongr Verhandl.* 1895;2:216–217.
2. Bircoll M. Cosmetic breast augmentation utilizing autologous fat and liposuction techniques. *Plast Reconstr Surg.* 1987;79:267–271.
3. Report on Autologous Fat Transplantation. ASPRS Ad-Hoc Committee on New Procedures, September 30, 1987. *Plast Surg Nurs.* 1987;7:140–141.
4. Veber M, Tourasse C, Toussoun G, Moutran M, Mojallal A, Delay E. Radiographic findings after breast augmentation by autologous fat transfer. *Plast Reconstr Surg.* 2011;127:1289–1299.
5. Rubin E. Breast imaging considerations in fat grafting to the breast. *Plast Reconstr Surg.* 2011;128:570e–571e.
6. Rubin JP, Yoshimura K. Mammographic changes after stem cell supplemented fat transfer compared with changes after breast reduction: A blinded study. Paper presented at: International Federation of Adipose Therapeutics and Science Annual Meeting, October 2, 2010, Dallas, Texas; and at the 27th Annual Meeting of the Northeastern Society of Plastic Surgeons, October 30, 2010, Washington, DC.
7. Coleman SR. Structural fat grafting: More than a permanent filler. *Plast Reconstr Surg.* 2006;118(Suppl):108S–120S.
8. Coleman SR. Structural fat grafting. *Aesthet Surg J.* 1998;18:386, 388.
9. Chajchir A. Fat injection: Long-term follow-up. *Aesthetic Plast Surg.* 1996;20:291–296.
10. Chajchir A, Benzaquen I. Fat-grafting injection for soft-tissue augmentation. *Plast Reconstr Surg.* 1989;84:921–934; discussion 935.
11. Jackson IT, Simman R, Tholen R, DiNick VD. A successful long-term method of fat grafting: Recontouring of a large subcutaneous postradiation thigh defect with autologous fat transplantation. *Aesthetic Plast Surg.* 2001;25:165–169.
12. Rigotti G, Marchi A, Galiè M, et al. Clinical treatment of radiotherapy tissue damage by lipoaspirate transplant: A healing process mediated by adipose-derived adult stem cells. *Plast Reconstr Surg.* 2007;119:1409–1422; discussion 1423–1424.
13. Fulton JE. Breast contouring with “gelled” autologous fat: A 10-year update. *Int J Cosmet Surg Aesth Dermatol.* 2003;5:155–163.
14. Spear SL, Wilson HB, Lockwood MD. Fat injection to correct contour deformities in the reconstructed breast. *Plast Reconstr Surg.* 2005;116:1300–1305.
15. Missana MC, Laurent I, Barreau L, Balleyquier C. Autologous fat transfer in reconstructive breast surgery: Indications, technique and results. *Eur J Surg Oncol.* 2007;33:685–690.
16. Kanchwala SK, Glatt BS, Conant EF, Bucky LP. Autologous fat grafting to the reconstructed breast: The management of acquired contour deformities. *Plast Reconstr Surg.* 2009;124:409–418.
17. Coleman SR, Saboeiro AP. Fat grafting to the breast revisited: Safety and efficacy. *Plast Reconstr Surg.* 2007;119:775–785; discussion 786–787.
18. Wang H, Jiang Y, Meng H, Yu Y, Qi K. Sonographic assessment on breast augmentation after autologous fat graft. *Plast Reconstr Surg.* 2008;122:36e–38e.
19. Yoshimura K, Sato K, Aoi N, Kurita M, Hirohi T, Harii K. Cell-assisted lipotransfer for cosmetic breast augmentation: Supportive use of adipose-derived stem/stromal cells. *Aesthet Plast Surg.* 2008;32:48–55.
20. Zocchi M, Zuliani F. Bicompartimental breast liposculpting. *Aesthetic Plast Surg.* 2008;32:313–328.
21. Delay E, Garson S, Toussoun G, Sinna R. Fat injection to the breast: Techniques, results, and indications based on 880 procedures over 10 years. *Aesthet Surg J.* 2009;29:360–376.
22. Yoshimura K, Asano Y, Aoi N, et al. Progenitor-enriched adipose tissue transplantation as rescue for breast implant complications. *Breast J.* 2010;16:169–175.
23. Ueberreiter K, von Finckenstein JG, Cromme F, Herold C, Tanzella U, Vogt PM. BEAULI: A new easy method for large volume fat grafts. *Handchir Mikrochir Plast Chir.* 2010;42:379–385.
24. Zheng DN, Li QF, Lei H, et al. Autologous fat grafting to the breast for cosmetic enhancement: Experience in 66 patients with long-term follow up. *J Plast Reconstr Aesthet Surg.* 2008;61:792–798.
25. Gutowski K; ASPS Fat Graft Task Force. Current application and safety of autologous fat grafts: A report of the ASPS fat graft task force. *Plast Reconstr Surg.* 2009;124:272–280.
26. American Society of Plastic Surgeons. Fat transfer/fat graft and fat injection: ASPS guiding principles. Available at: <http://www.plasticsurgery.org/Documents/medical-professionals/health-policy/guiding-principles/ASPS-Fat-Transfer-Graft-Guiding-Principles.pdf>. Accessed April 11, 2011.
27. Rigotti G, Marchi A, Stringhini P, et al. Determining the oncological risk of autologous lipoaspirate grafting for post-mastectomy breast reconstruction. *Aesthetic Plast Surg.* 2010;34:475–480.
28. Carpaneda CA, Ribeiro MT. Percentage of graft viability versus injected volume in adipose autotransplants. *Aesthetic Plast Surg.* 1994;18:17–19.
29. Fagrell D, Eneström S, Berggren A, Kniola B. Fat cylinder transplantation: An experimental comparative study of three different kinds of fat transplants. *Plast Reconstr Surg.* 1996;98:90–96; discussion 97–98.
30. Guerrero Santos J, Gonzalez-Mendoza A, Masmela Y, Gonzalez MA, Deos M, Diaz P. Long-term survival of free fat grafts in muscle: An experimental study in rats. *Aesthetic Plast Surg.* 1996;20:403–408.
31. Lalikos JF, Li YQ, Roth TP, Doyle JW, Matry WE, Lawrence WT. Biochemical assessment of cellular damage after adipocyte harvest. *J Surg Res.* 1997;70:95–100.
32. Guerrero Santos J. Simultaneous rhytidoplasty and lipoinjection: A comprehensive aesthetic surgical strategy. *Plast Reconstr Surg.* 1998;102:191–199.
33. Berman M. Rejuvenation of the upper eyelid complex with autologous fat transplantation. *Dermatol Surg.* 2000;26:1113–1116.
34. Cortese A, Savastano G, Felicetta L. Free fat transplantation for facial tissue augmentation. *J Oral Maxillofac Surg.* 2000;58:164–169; discussion 169–170.
35. Erol OO. Facial autologous soft-tissue contouring by adjuvant of tissue cocktail injection (micrograft and mini-graft mixture of dermis, fascia, and fat). *Plast Reconstr Surg.* 2000;106:1375–1387; discussion 1388–1389.
36. Reiche-Fischel O, Wolford LM, Pitta M. Facial contour reconstruction using an autologous free fat graft: A case report with 18-year follow-up. *J Oral Maxillofac Surg.* 2000;58:103–106.
37. Fulton JE Jr, Rahimi AD, Helton P, Watson T, Dahlberg K. Lip rejuvenation. *Dermatol Surg.* 2000;26:470–474; discussion 474–475.
38. Niechajev I. Lip enhancement: Surgical alternatives and histologic aspects. *Plast Reconstr Surg.* 2000;105:1173–1183; discussion 1184–1187.

39. Latoni JD, Marshall DM, Wolfe SA. Overgrowth of fat autotransplanted for correction of localized steroid-induced atrophy. *Plast Reconstr Surg*. 2000;106:1566–1569.
40. Shiffman MA, Mirrafati S. Fat transfer techniques: The effect of harvest and transfer methods on adipocyte viability and review of the literature. *Dermatol Surg*. 2001;27:819–826.
41. MacRae JW, Tholpady SS, Ogle RC, Morgan RF. Ex vivo fat graft preservation: Effects and implications of cryopreservation. *Ann Plast Surg*. 2004;52:281–282; discussion 283.
42. Baran CN, Celebioğlu S, Sensöz O, Ulusoy G, Civielek B, Ortak T. The behavior of fat grafts in recipient areas with enhanced vascularity. *Plast Reconstr Surg*. 2002;109:1646–1651, 1652.
43. Huss FR, Kratz G. Adipose tissue processed for lipoinjection shows increased cellular survival in vitro when tissue engineering principles are applied. *Scand J Plast Reconstr Surg Hand Surg*. 2002;36:166–171.
44. Bernard RW, Beran SJ. Autologous fat graft in nipple reconstruction. *Plast Reconstr Surg*. 2003;112:964–968.
45. Monreal J. Fat tissue as a permanent implant: New instruments and refinements. *Aesthet Surg J*. 2003;23:213–216.
46. Dasiou-Plakida D. Fat injections for facial rejuvenation: 17 years experience in 1720 patients. *J Cosmet Dermatol*. 2003;2:119–125.
47. Kwak JY, Lee SH, Park HL, Kim JY, Kim SE, Kim EK. Sonographic findings in complications of cosmetic breast augmentation with autologous fat obtained by liposuction. *J Clin Ultrasound*. 2004;32:299–301.
48. Murillo WL. Buttock augmentation: Case studies of fat injection monitored by magnetic resonance imaging. *Plast Reconstr Surg*. 2004;114:1606–1614; discussion 1615–1616.
49. Kuran I, Tümerdem B. A new simple method used to prepare fat for injection. *Aesthetic Plast Surg*. 2005;29:18–22; discussion 23.
50. Ellenbogen R, Youn A, Yamini D, Svehlak S. The volumetric face lift. *Aesthetic Surg J*. 2004;24:514–522.
51. Karabulut AB, Tümerdem B. Obtaining predictable results in malar augmentation with preimplant fat injection. *Plast Reconstr Surg*. 2004;114:1974–1975.
52. Serra-Renom JM, Fontdevila J. Treatment of facial fat atrophy related to treatment with protease inhibitors by autologous fat injection in patients with human immunodeficiency virus infection. *Plast Reconstr Surg*. 2004;114:551–555; discussion 556–557.
53. Rehman J, Traktuev D, Li J, et al. Secretion of angiogenic and antiapoptotic factors by human adipose stromal cells. *Circulation*. 2004;109:1292–1298.
54. Pu LL, Cui X, Fink BF, Cibull ML, Gao D. The viability of fatty tissues within adipose aspirates after conventional liposuction: A comprehensive study. *Ann Plast Surg*. 2005;54:288–292; discussion 292.
55. Karacaoglu E, Kizilkaya E, Cermik H, Zienowicz R. The role of recipient sites in fat-graft survival: Experimental study. *Ann Plast Surg*. 2005;55:63–68; discussion 68.
56. Domergue S, Psomas C, Yachouh J, et al. Fat microinfiltration autografting for facial restructuring in HIV patients. *J Craniomaxillofac Surg*. 2006;34:484–488.
57. Yi C, Pan Y, Zhen Y, et al. Enhancement of viability of fat grafts in nude mice by endothelial progenitor cells. *Dermatol Surg*. 2006;32:1437–1443.
58. Torio-Padron N, Baerlecken N, Momeni A, Stark GB, Borges J. Engineering of adipose tissue by injection of human preadipocytes in fibrin. *Aesthetic Plast Surg*. 2007;31:285–293.
59. Witort EJ, Pattarino J, Papucci L, et al. Autologous lipofilling: Coenzyme Q10 can rescue adipocytes from stress-induced apoptotic death. *Plast Reconstr Surg*. 2007;119:1191–1199.
60. Yi CG, Xia W, Zhang LX, et al. VEGF gene therapy for the survival of transplanted fat tissue in nude mice. *J Plast Reconstr Aesthet Surg*. 2007;60:272–278.
61. Saxena V, Orgill D, Kohane I. A set of genes previously implicated in the hypoxia response might be an important modulator in the rat ear tissue response to mechanical stretch. *BMC Genomics*. 2007;8:430.
62. Saxena V, Hwang CW, Huang S, Eichbaum Q, Ingber D, Orgill DP. Vacuum-assisted closure: Microdeformations of wounds and cell proliferation. *Plast Reconstr Surg*. 2004;114:1086–1096; discussion 1097–1098.
63. Rennekampff HO, Reimers K, Gabka CJ, et al. Current perspective and limitations of autologous fat transplantation—“consensus meeting” of the German Society of Plastic, Reconstructive and Aesthetic Surgeons at Hannover; September 2009 (in German). *Handchir Mikrochir Plast Chir*. 2010;42:137–142.
64. Rhodes NP. Inflammatory signals in the development of tissue-engineered soft tissue. *Biomaterials*. 2007;28:5131–5136.
65. Piasecki JH, Moreno K, Gutowski KA. Beyond the cells: Scaffold matrix character affects the in vivo performance of purified adipocyte fat grafts. *Aesthet Surg J*. 2008;28:306–312.
66. Itoi Y, Takatori M, Hyakusoku H, Mizuno H. Comparison of readily available scaffolds for adipose tissue engineering using adipose-derived stem cells. *J Plast Reconstr Aesthet Surg*. 2010;63:858–864.
67. von Heimburg D, Lemperle G, Dippe B, Krüger S. Free transplantation of fat autografts expanded by tissue expanders in rats. *Br J Plast Surg*. 1994;47:470–476.
68. Moisisidis E, Heath T, Boorer C, Ho K, Deva AK. A prospective, blinded, randomized, controlled clinical trial of topical negative pressure use in skin grafting. *Plast Reconstr Surg*. 2004;114:917–922.
69. Kannan RY, Salacinski HJ, Sales K, Butler P, Seifalian AM. The roles of tissue engineering and vascularisation in the development of micro-vascular networks: A review. *Biomaterials*. 2005;26:1857–1875.
70. Khouri R, Del Vecchio D. Breast reconstruction and augmentation using pre-expansion and autologous fat transplantation. *Clin Plast Surg*. 2009;36:269–280.
71. Peer LA. Loss of weight and volume in human fat grafts: With postulation of a “cell survival theory.” *Plast Reconstr Surg*. 1950;5:217–230.
72. Peer LA. The neglected free fat graft: Its behavior and clinical use. *Am J Surg*. 1956;92:40–47.
73. Khouri RK, Schlenz I, Murphy BJ, Baker TJ. Nonsurgical breast enlargement using an external soft-tissue expansion system. *Plast Reconstr Surg*. 2000;105:2500–2512; discussion 2513–2514.
74. Greco RJ. Nonsurgical breast enhancement: Fact or fiction? *Plast Reconstr Surg*. 2002;110:337–339.
75. Smith CJ, Khouri RK, Baker TJ. Initial experience with the Brava non-surgical system of breast enhancement. *Plast Reconstr Surg*. 2002;110:1593–1595.
76. Khouri RK, Rorich RJ, Baker TJ. Multicenter evaluation of an external tissue expander system (Brava) for breast enlargement. Presented at the 71st Annual Scientific Meeting of ASPS/PSEF/ASMS; November 2–6, 2002; San Antonio, Texas. *Plast Surg Forum*. 2002;96:168–171.
77. Schlenz I, Kaider A. The Brava external tissue expander: Is breast enlargement without surgery a reality? *Plast Reconstr Surg*. 2007;120:1680–1689; discussion 1690–1691.

78. Lantieri LA, Martin-Garcia N, Wechsler J, Mitrofanoff M, Raulo Y, Baruch J. Vascular endothelial growth factor expression in expanded tissue: A possible mechanism of angiogenesis in tissue expansion. *Plast Reconstr Surg*. 1998;101:392–398.
79. Herold C, Knobloch K, Stieglitz LH, Samii A, Vogt PM. Magnetic resonance imaging-based breast volumetry in breast surgery: A transfer from neurosurgery. *Plast Reconstr Surg*. 2010;125:17e–19e.
80. Noordzij M, Tripepi G, Dekker FW, Zoccali C, Tanck MW, Jager KJ. Sample size calculations: Basic principles and common pitfalls. *Nephrol Dial Transplant*. 2010;25:1388–1393.
81. Wassertheil-Smoller S, Kim MY. Statistical analysis of clinical trials. *Semin Nucl Med*. 2010;40:357–363.
82. U.S. Department of Health and Human Services Food and Drug Administration, Center for Drug Evaluation and Research, Center for Biologics Evaluation and Research. Guidance for Industry: E 10 Choice of Control Groups and Related Issues in Clinical Trials. Available at: <http://www.fda.gov/downloads/RegulatoryInformation/Guidances/ucm129460.pdf>. Accessed April 11, 2011.
83. Coleman SR. Facial recontouring with lipostructure. *Clin Plast Surg*. 1997;24:347–367.
84. Duskova M, Kristen M. Augmentation by autologous adipose tissue in cleft lip and nose: Final esthetic touches in clefts. Part I. *J Craniofac Surg*. 2004;15:478–481; discussion 482.
85. Bertossi D, Zancanaro C, Trevisiol L, Albanese M, Ferrari F, Nocini PF. Lipofilling of the lips. *Arch Facial Plast Surg*. 2003;5:392–398.
86. Cardenas Restrepo JC, Muñoz Ahmed JA. Large-volume lipoinjection for gluteal augmentation. *Aesthet Surg J*. 2002;22:33–38.
87. Roberts TL III, Toledo LS, Badin AZ. Augmentation of the buttocks by micro fat grafting. *Aesthet Surg J*. 2001;21:311–319.
88. Harrison D, Selvaggi G. Gluteal augmentation surgery: Indications and surgical management. *J Plast Reconstr Aesthet Surg*. 2007;60:922–928.
89. Bucky LP, Percec I. The science of autologous fat grafting: Views on current and future approaches to neoadipogenesis. *Aesthet Surg J*. 2008;28:313–321.
90. Butterwick KJ. Lipoaugmentation for aging hands: A comparison of the longevity and aesthetic results of centrifuged versus noncentrifuged fat. *Dermatol Surg*. 2002;28:987–991.
91. Karacalar A, Orak I, Kaplan S, Yildirim S. No-touch technique for autologous fat harvesting. *Aesthetic Plast Surg*. 2004;28:158–164.
92. Rohrich RJ, Sorokin ES, Brown SA. In search of improved fat transfer viability: A quantitative analysis of the role of centrifugation and harvest site. *Plast Reconstr Surg*. 2004;113:391–395; discussion 396–397.
93. Smith P, Adams WP Jr, Lipschitz AH, et al. Autologous human fat grafting: Effect of harvesting and preparation techniques on adipocyte graft survival. *Plast Reconstr Surg*. 2006;117:1836–1844.
94. Nordström RE, Wang J, Fan J. “Spaghetti” fat grafting: A new technique. *Plast Reconstr Surg*. 1997;99:917–918.
95. Ersek RA, Chang P, Salisbury MA. Lipo layering of autologous fat: An improved technique with promising results. *Plast Reconstr Surg*. 1998;101:820–826.
96. Shoshani O, Ullmann Y, Shupak A, et al. The role of frozen storage in preserving adipose tissue obtained by suction-assisted lipectomy for repeated fat injection procedures. *Dermatol Surg*. 2001;27:645–647.
97. Burnouf M, Buffet M, Schwarzing M, et al. Evaluation of Coleman lipostructure for treatment of facial lipoatrophy in patients with human immunodeficiency virus and parameters associated with the efficiency of this technique. *Arch Dermatol*. 2005;141:1220–1224.
98. Ellenbogen R, Motykie G, Youn A, Svehlak S, Yamini D. Facial reshaping using less invasive methods. *Aesthet Surg J*. 2005;25:144–152.
99. Ozsoy Z, Kul Z, Bilir A. The role of cannula diameter in improved adipocyte viability: A quantitative analysis. *Aesthet Surg J*. 2006;26:287–289.
100. Rose JG Jr, Lucarelli MJ, Lemke BN, et al. Histologic comparison of autologous fat processing methods. *Ophthal Plast Reconstr Surg*. 2006;22:195–200.
101. Piasecki JH, Gutowski KA, Moreno KM, Lahvis GL. Purified viable fat suspended in matrigel improves volume longevity. *Aesthet Surg J*. 2008;28:24–32.
102. Hu S, Zhang H, Feng Y, et al. Introduction of an easy technique for purification and injection of autogenous free fat parcels in correcting of facial contour deformities. *Ann Plast Surg*. 2007;58:602–607.
103. Kaufman MR, Bradley JP, Dickinson B, et al. Autologous fat transfer national consensus survey: Trends in techniques for harvest, preparation, and application, and perception of short- and long-term results. *Plast Reconstr Surg*. 2007;119:323–331.
104. Gonzalez AM, Lobocki C, Kelly CP, Jackson IT. An alternative method for harvest and processing fat grafts: An in vitro study of cell viability and survival. *Plast Reconstr Surg*. 2007;120:285–294.
105. Piasecki JH, Gutowski KA, Lahvis GP, Moreno KI. An experimental model for improving fat graft viability and purity. *Plast Reconstr Surg*. 2007;119:1571–1583.
106. Karaçal N, Cobanoğlu U, Ambarcıoğlu O, Kutlu N. The effect of fibrin glue on fat graft survival. *J Plast Reconstr Aesthet Surg*. 2007;60:300–303.
107. Rubin JP, Bennett JM, Doctor JS, Tebbets BM, Marra KG. Collagenous microbeads as a scaffold for tissue engineering with adipose-derived stem cells. *Plast Reconstr Surg*. 2007;120:414–424.
108. Torio-Padron N, Baerlecken N, Momeni A, Stark GB, Borges J. Engineering of adipose tissue by injection of human preadipocytes in fibrin. *Aesthetic Plast Surg*. 2007;31:285–293.
109. De Ugarte DA, Ashjian PH, Elbarbary A, Hedrick MH. Future of fat as raw material for tissue regeneration. *Ann Plast Surg*. 2003;50:215–219.
110. Markey AC, Glogau RG. Autologous fat grafting: Comparison of techniques. *Dermatol Surg*. 2000;26:1135–1139.
111. Kurita M, Matsumoto D, Shigeura T, et al. Influences of centrifugation on cells and tissues in liposuction aspirates: Optimized centrifugation for lipotransfer and cell isolation. *Plast Reconstr Surg*. 2008;121:1033–1041; discussion 1042–1043.
112. Chajchir A, Benzaquen I, Moretti E. Comparative experimental study of autologous adipose tissue processed by different techniques. *Aesthetic Plast Surg*. 1993;17:113–115.
113. Fournier PF. Fat grafting: My technique. *Dermatol Surg*. 2000;26:1117–1128.
114. Matsumoto D, Sato K, Gonda K, et al. Cell-assisted lipotransfer: Supportive use of human adipose-derived cells for soft tissue augmentation with lipoinjection. *Tissue Eng*. 2006;12:3375–3382.
115. De Fillippo RE, Atala A. Stretch and growth: The molecular and physiological influences of tissue expansion. *Plast Reconstr Surg*. 2002;109:2450–2462.

116. Kato H, Suga H, Eto H, et al. Reversible adipose tissue enlargement induced by external tissue suspension: Possible contribution of basic fibroblast growth factor in the preservation of enlarged tissue. *Tissue Eng Part A* 2010;16:2029–2040.
117. Moisidis E, Heath T, Boorer C, Ho K, Deva AK. A prospective, blinded, randomized, controlled clinical trial of topical negative pressure use in skin grafting. *Plast Reconstr Surg*. 2004;114:917–922.
118. Genecov DG, Schneider AM, Morykwas MJ, Parker D, White WL, Argenta LC. A controlled subatmospheric dressing increases the rate of skin graft donor site reepithelialization. *Ann Plast Surg*. 1998;40:219–225.
119. Dolderer JH, Abberton KM, Thompson EW, et al. Spontaneous large volume adipose tissue generation from a vascularized pedicled fat flap inside a chamber space. *Tissue Eng*. 2007;13:673–681.
120. Bucky LP, Godek CP. The behavior of fat grafts in recipient areas with enhanced vascularity (Discussion). *Plast Reconstr Surg*. 2002;109:1652.
121. Karacaoglu E, Kizilkaya E, Cermik H, Zienowicz R. The role of recipient sites in fat-graft survival: Experimental study. *Ann Plast Surg*. 2005;55:63–68; discussion 68.
122. Wong VW, Rustad KC, Longaker MT, Gurtner GC. Tissue engineering in plastic surgery: A review. *Plast Reconstr Surg*. 2010;126:858–868.
123. Park B, Kong JS, Kang S, Kim YW. The effect of epidermal growth factor on autogenous fat graft. *Aesthetic Plast Surg*. 2011;35:738–744.
124. Samdal F, Skolleborg KC, Berthelsen B. The effect of preoperative needle abrasion of the recipient site on survival of autologous free fat grafts in rats. *Scand J Plast Reconstr Surg Hand Surg*. 1992;26:33–36.
125. Yamaguchi M, Matsumoto F, Bujo H, et al. Revascularization determines volume retention and gene expression by fat grafts in mice. *Exp Biol Med (Maywood)* 2005;230:742–748.
126. Clavijo-Alvarez JA, Rubin JP, Bennett J, et al. A novel perfluoroelastomer seeded with adipose-derived stem cells for soft-tissue repair. *Plast Reconstr Surg*. 2006;118:1132–1142; discussion 1143–1144.
127. Yazawa M, Mori T, Tuchiya K, Nakayama Y, Ogata H, Nakajima T. Influence of vascularized transplant bed on fat grafting. *Wound Repair Regen*. 2006;14:586–592.
128. Lu F, Li J, Gao J, et al. Improvement of the survival of human autologous fat transplantation by using VEGF-transfected adipose-derived stem cells (Discussion). *Plast Reconstr Surg*. 2009;124:1437–1446.
129. Pu LL. Improvement of the survival of human autologous fat transplantation by using VEGF-transfected adipose-derived stem cells (Discussion). *Plast Reconstr Surg*. 2009;124:1447–1449.
130. Aygit AC, Sarikaya A, Doganay L, Top H, Cakir B, Firat MF. The fate of intramuscularly injected fat autografts: An experimental study in rabbits. *Aesthetic Plast Surg*. 2004;28:334–339.
131. Majd H, Wipff PJ, Buscemi L, et al. A novel method of dynamic culture surface expansion improves mesenchymal stem cell proliferation and phenotype. *Stem Cells* 2009;27:200–209.
132. Vogel V, Sheetz M. Local force and geometry sensing regulate cell functions. *Nat Rev Mol Cell Biol*. 2006;7:265–275.
133. Matthews BD, Overby DR, Mannix R, Ingber DE. Cellular adaptation to mechanical stress: Role of integrins, Rho, cytoskeletal tension and mechanosensitive ion channels. *J Cell Sci*. 2006;119:508–518.
134. Khouri RK, Hong SP, Deune EG, et al. De novo generation of permanent neovascularized soft tissue appendages by platelet-derived growth factor. *J Clin Invest*. 1994;94:1757–1763.
135. Dolderer JH, Abberton KM, Thompson EW, et al. Spontaneous large volume adipose tissue generation from a vascularized pedicled fat flap inside a chamber space. *Tissue Eng*. 2007;13:673–681.
136. Stillaert F, Findlay M, Palmer J, et al. Host rather than graft origin of Matrigel-induced adipose tissue in the murine tissue-engineering chamber. *Tissue Eng*. 2007;13:2291–2300.
137. Hedén P, Adams WP Jr, Maxwell P, Nava M, Schefflan M, Stan C. Aesthetic breast surgery: Consulting for the future. Proposals for improving doctor-patient interactions. *Aesthetic Plast Surg*. 2009;33:388–394; discussion 395.
138. Del Vecchio DA, Bucky LP. Breast augmentation using pre-expansion and autologous fat transplantation: A clinical radiographic study. *Plast Reconstr Surg*. 2011;127:2441–2450.
139. Baltzer PA, Benndorf M, Dietzel M, Gajda M, Runnebaum IB, Kaiser WA. False-positive findings at contrast-enhanced breast MRI: A BI-RADS descriptor study. *AJR Am J Roentgenol*. 2010;194:1658–1663.
140. Delay E, Scevola A, Toussoun G, Grecea G, Gosset J, Veber M. Efficacité et sécurité du lipomodélage dans la correction des séquelles de traitement conservateur du cancer du sein. Paper presented at: 55th Congress of the National Société Française de Chirurgie Plastique Reconstructrice et Esthétique; November 22, 2010; Paris, France.
141. Fraser JK, Hedrick MH, Cohen SR. Oncologic risks of autologous fat grafting to the breast. *Aesthet Surg J*. 2011;31:68–75.